

CHANCROID - DOWN BUT NOT OUT

LESSONS FROM A CASE REPORT

P Barnes DipGUM. M Chauhan MD FRCOG

New Croft Centre for Sexual Health

Background

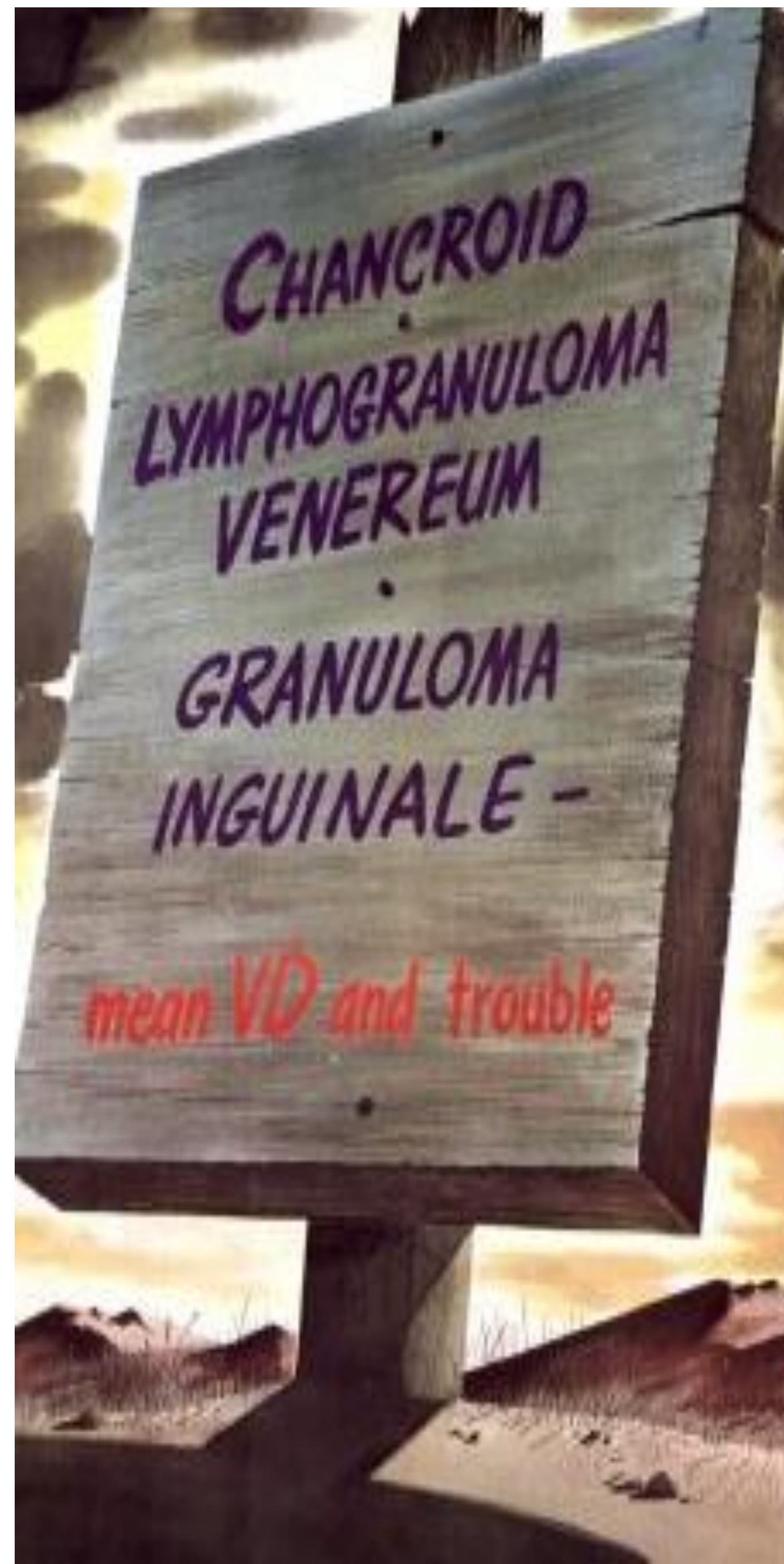
Chancroid was common at the turn of the twentieth century, and was a major cause of morbidity during the first and second world wars.

It is now however a rare cause of genital ulcer disease (GUD) in industrialised countries.

In 2011, 67 cases were recorded in England.

Chancroid is caused by the gram negative coccobacillus *Haemophilus ducreyi* and is characterised by painful genital ulcers accompanied in 10 to 40% of patients by inguinal lymphadenitis or bubo formation

It is possible that it is under recorded as it is easily treated with single dose azithromycin and has features which are highly suggestive of herpes simplex virus (HSV)



Images from the History of Medicine Archives - US Naval School 1946

History of Case report

- 22 year old local white heterosexual male
- No history of contact with a non UK resident.
- Symptomatic with excruciatingly painful penile ulcers. for 6 weeks prior to diagnosis. (He was unable to sleep or carry out normal activities)
- He presented to our service 3 times.
- Investigations for syphilis, HSV, lymphogranuloma venerum, chlamydia, gonorrhoea and HIV were all negative.
- He also attended 2 other GUM services, a walk in centre and an accident and emergency service.
- Despite 4 negative HSV PCRs and an impressive self diagnosis of chancroid (he consulted the internet) he was repeatedly offered aciclovir.

Objectives

We wish to highlight the importance of considering chancroid in cases of GUD where polymerase chain reaction (PCR) testing for HSV and syphilis tests ((PCR/serology/dark ground microscopy) are negative.

Discussion

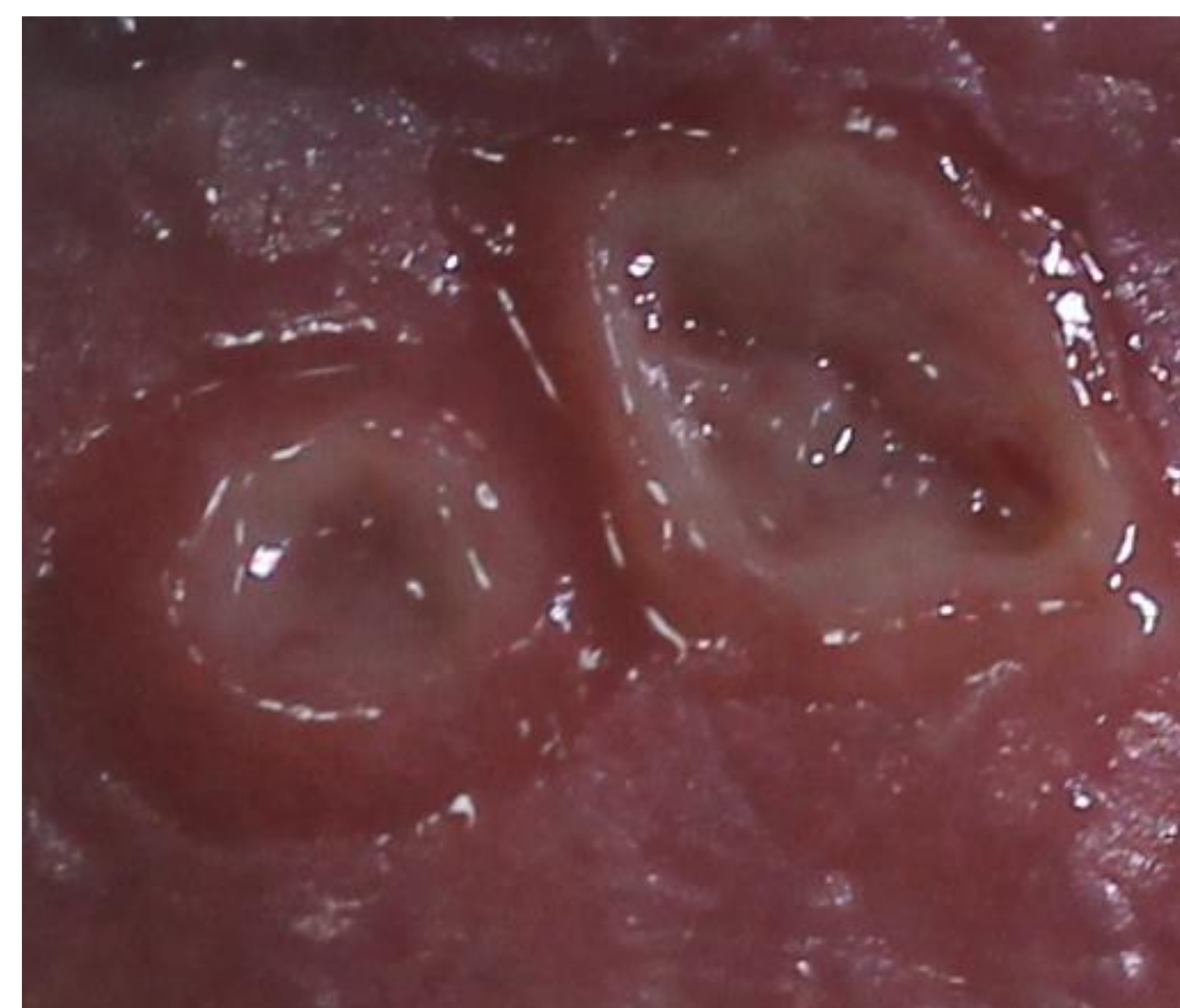
As clinicians we are very likely to miss cases such as this where the patient has no obvious non-UK contacts.

It may be that chancroid is in fact more common than we think.

Multiplex PCR testing for H.Ducrei (95% sensitivity) is more reliable than culture or microscopy

Chancroid is easily treated with single dose oral azithromycin 1gm.

- On his last 2 attendances he explained his self diagnosis and requested erythromycin.
- He only succeeded in getting treatment however by threatening to kill himself!
- We made the diagnosis using multiplex PCR testing just after he commenced erythromycin.
- At that time he had 3 painful, deep ulcers with raised edges on the frenulum and coronal sulcus of his penis. He also had mild bilateral inguinal lymphadenopathy.
- Contact tracing was initiated but no other cases were identified.



Chancroid ulcers showing typical features:

- Deep and ragged
- Raised, under-mined edges
- Necrotic with a sloughy yellow/grey base.

Key Learning Points

- 1.Chancroid as a cause of GUD is rare in the developed world but still occurs and should not be forgotten
- 2.In cases of GUD where swabs for HSV and syphilis tests (PCR/serology/dark ground microscopy) are negative, it is important to consider chancroid in the differential.
- 3.Single dose oral azithromycin is effective in treating chancroid and should be considered in the treatment options.

References: Upon application

Kissing chancroid ulcers presenting in a classical site on the sub-prepuce and coronal sulcus.

Extremely painful.

Non-indurated and friable.

